



# Volumizing Viaducts of the Midface: Defining the Beut Techniques

Christopher Surek, DO; Javier Beut, MD; Robert Stephens, PhD;  
Jerome Lamb, MD; and Glenn Jelks, MD

Aesthetic Surgery Journal  
2015, Vol 35(2) 121–134  
© 2015 The American Society for  
Aesthetic Plastic Surgery, Inc.  
Reprints and permission:  
journals.permissions@oup.com  
DOI: 10.1093/asj/sju073  
www.aestheticsurgeryjournal.com

**OXFORD**  
UNIVERSITY PRESS

## Abstract

**Background:** In nonsurgical facial rejuvenation, autologous fat and dermal fillers have become an effective method to achieve symmetry and balance of the midface. Nonsurgical techniques that target the dynamic anatomical relationships existing in the midface can improve rejuvenation outcomes in this commonly augmented region.

**Objectives:** The authors described techniques for fat compartment and potential space volumization of the midface via a standardized and reproducible technique. They placed emphasis on access to anatomical spaces and compartments within the midface.

**Methods:** In 11 hemifacial cadavers, hyaluronic acid filler homogenized with red dye was injected via 3 midfacial ports that were anatomically designed to access the superficial fat compartments, deep fat compartments, or traverse the prezygomatic space. Specimens were dissected in a layered fashion to analyze relationships between the injected filler and midfacial anatomy. We have described 4 site-specific procedural techniques and created a video containing anatomical renderings of each targeted viaduct accompanied by technique demonstrations.

**Results:** We found that Beut techniques 1 through 4 can be performed through 3 midfacial viaducts. Port placement 1.5 cm inferolateral to the alar base in the nasolabial crease created a medial midface viaduct, suitable for access to the deep medial cheek fat, medial superficial fat compartment, premaxillary space, and adjacent superior nasolabial cheek compartment. Port placement within the nasojugal groove provided a middle midface viaduct to access the middle superficial fat compartment and medial suborbicularis oculi fat (SOOF). Port placement 1.5 cm inferolateral to the lateral canthus created a lateral midface viaduct to approach the pre-periosteal fat, prezygomatic space, lateral SOOF, and infraorbital fat compartment.

**Conclusions:** Our findings indicate that anterior and lateral cheek projection, V-deformity correction, rhytid softening, and tear trough effacement can be achieved through the midfacial viaducts. Systematic assessment and site-specific nonsurgical rejuvenation of the midface may lead to increased safety, accuracy, and technique reproducibility in this commonly injected region.

Accepted for publication October 6, 2014.

*No rellenés agujeros, da soporte y forma.*

*[Do Not Fill Holes, Give Shape and Support.]*

Javier Beut

The achievement of consistent artistry and the reproducibility of midfacial volumization procedures requires comprehension of the fat compartments, ligamentous support, the membranous orbicularis envelope, and the potential spaces contained in the midfacial framework.<sup>1-25</sup> Though many areas of the aging face can benefit from volumizing procedures, a nonsystematic approach to the midface can be humbling to the clinician and more than disappointing for the patient. Failure analysis of those disappointing cases can be difficult because our record keeping is often a two-dimensional scribblegram or a dictated sequence of volumes placed in areas where clinicians do not have a clear understanding of the

Dr Surek is a Resident Physician in the Department of Plastic Surgery, University of Kansas Medical Center, Kansas City, Kansas. Dr Beut is a plastic surgeon in private practice in Palma de Mallorca, Spain.

Dr Stephens is Chairman of the Department of Anatomy, Kansas City University of Medicine and Biosciences, Kansas City, Missouri.

Dr Lamb is a plastic surgeon in private practice in Independence, Missouri. Dr Jelks is Associate Professor, Department of Plastic and Reconstructive Surgery, New York University, New York, New York.

## Corresponding Author:

Dr Christopher Surek, Department of Plastic Surgery, University of Kansas Medical Center, 3901 Rainbow Blvd, Mailstop 3015, Kansas City, KS 66160.

E-mail: csurek@kumc.edu

Presented at: IMCAS Annual World Congress 2013 in Paris, France in January/February 2013; ASAPS Aesthetic Symposium in Las Vegas, NV in January 2014; and the American Society for Aesthetic Plastic Surgery in San Francisco, CA in April 2014.

anatomical spaces injected. Needle injection does not afford the clinician a feel for what tissue space has been entered and entails a greater risk of intravascular injection.

The tendency for some injectors to fill depressions or folds yields suboptimal facial shape during dynamic movement. When examining the contour in young faces or artists' renditions of facial beauty, we find a unified element of shape and support. We believe that simply filling surface clefts without addressing the support structures that create them can yield incongruence. Compartment-specific augmentation of the deep medial cheek fat pad (DMCF) and lateral SOOF has been described for contour corrections in the anterior and lateral cheek, respectively.<sup>1,4,21</sup> This technique has been postulated in anatomical studies but has not been confirmed through clinical studies. Safe and accurate techniques for accessing these compartments are not well documented. Discovery of the prezygomatic and premaxillary space and their anatomical implications for rhytidectomies and midface cheek lifts are well documented.<sup>14,22</sup> The utility of these spaces for injection-based procedures has not been described. We have recently introduced the concept of midfacial viaducts as preformed access portals to aesthetic target zones in the midface.<sup>24</sup>

The purpose of our study is to describe techniques for fat compartment and potential space volumization of the midface via our described viaduct method. Furthermore, the adoption of an anatomically-based approach to the midface affords an efficiency and accuracy in record keeping. Lastly, we address composition and density differences between autologous fat and dermal fillers and their role in achieving desired aesthetic goals. The techniques presented were originated in 2006 by Dr Javier Beut, during the time he conducted an FDA trial for Restylane SubQ (Galderma, Fort Worth, TX).<sup>26,27</sup> They have been adjusted and improved through the work of 3 practitioners using injectables in their clinical practice and several workshops worldwide, emphasizing anatomy and safety.<sup>24,26-33</sup> Our emphasis is placed on giving shape and support to the face as opposed to merely filling holes or clefts.

## METHODS

### Study Design

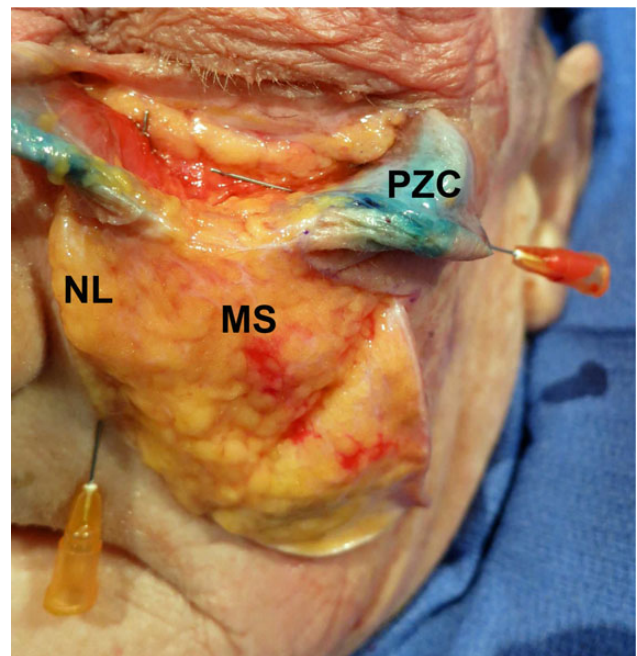
This fresh cadaveric study was conducted from July 2012 to May 2014. After obtaining Institutional Review Board approval by Kansas City University of Medicine and Biosciences (KCUMB), Kansas City, MO, the authors performed dissections on 6 donated specimens at KCUMB. Five additional dissections were performed at national meetings as part of instructional cadaver courses.

### Techniques

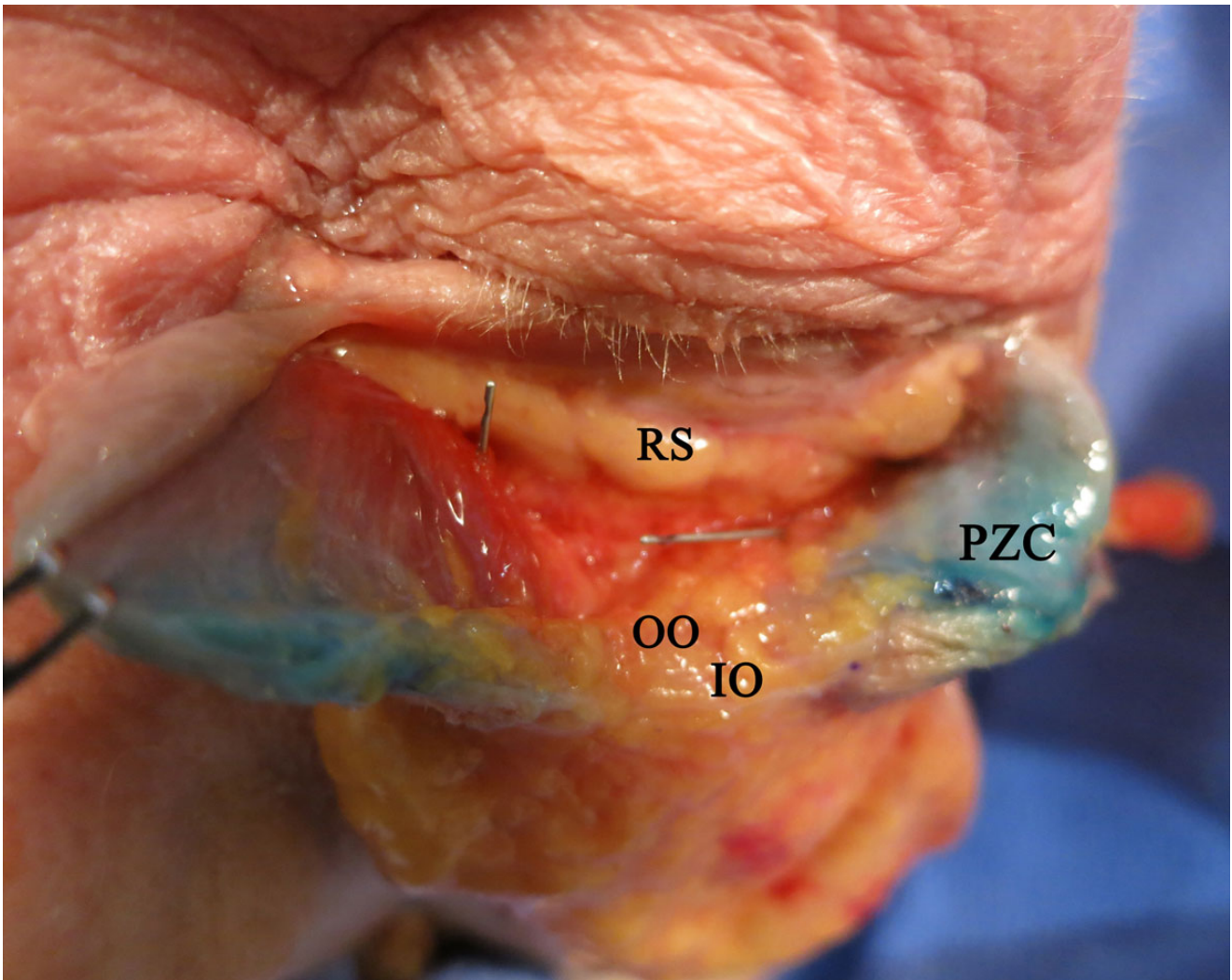
Hyaluronic acid filler was homogenized with red dye and injected into defined midface viaducts in 11 hemifacial

cadavers (Figures 1-5 and 7). The investing capsule of the orbicularis oculi was dyed with methylene blue for identification purposes. Each specimen was dissected under loupe magnification in a layered fashion. Layer 1 consisted of a skin-only flap that was elevated medial to lateral from the alar base with a transverse incision caudal to the surface anatomy of the orbitomalar ligament. Layer 2 consisted of the superficial midface fat compartments—nasolabial, medial superficial, middle superficial, and infraorbital malar compartments (Figures 1-5 and 7).<sup>1,21</sup> With layer 2 reflected laterally, the undersurface of the superficial musculoaponeurotic system (SMAS) was visualized on the reflected layer; the mimetic muscles were identified along with underlying deep midface fat compartments, including the medial and lateral SOOF and the DMCF. The SOOF was adherent to the undersurface of the Orbicularis Oculi muscle. Beneath the SOOF lies the encapsulated prezygomatic space with overlies PP fat. Beneath the SOOF, the preperiosteal (PP) fat was visualized (Figures 2, 3 and 5).

The location of the dyed hyaluronic acid and surrounding anatomy were observed and documented. The anatomical relationships for each midface viaduct were analyzed based on the correlation between filler placement and pertinent anatomical structures. Techniques to effectively approach aesthetically significant anatomical architecture have been described in figure 7 and the supplementary videos, *Beut Midface Injection Types 1-4*.



**Figure 1.** This elderly male fresh cadaver underwent a layered dissection of the midface following a percutaneous injection of red-dyed hyaluronic acid with blunt cannula through two insertion ports. The nasolabial (NL) fat compartment and the medial superficial (MS) cheek fat compartment are labeled. The prezygomatic space capsule (PZC) is dyed with methylene blue.



**Figure 2.** This elderly male fresh cadaver underwent a layered dissection of the midface following percutaneous injection of red-dyed hyaluronic acid with blunt cannula through two insertion ports. The arcus marginalis was released, revealing the red-stained material within the prezygomatic space (PZS). The infraorbital (IO) fat compartment, orbicularis oculi (OO) muscle, and retroseptal (RS) fat are labeled for orientation. The prezygomatic space capsule (PZC) is dyed with methylene blue.

## RESULTS

The average age of the 6 hemifacial specimens, dissected at KCUMB, was 82 years (range, 80-84 years), and all cadavers at the national meetings were also elderly specimens.

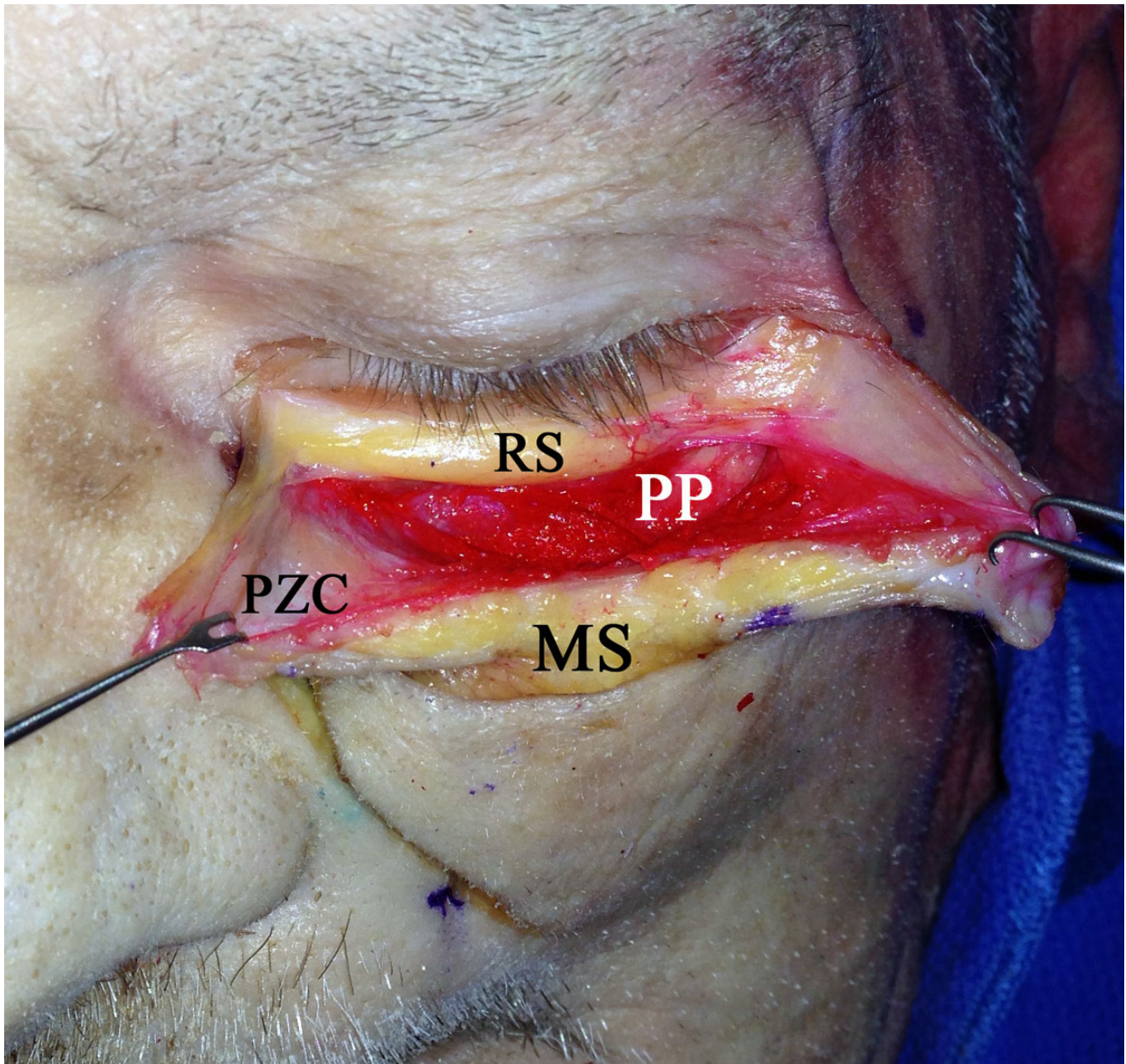
We found that the following described techniques could be performed through 3 insertion ports—the “lateral cheek insertion port,” the “nasojugal insertion port,” and the “nasolabial insertion port.” The lateral cheek insertion port is in line with the supratarsal fold, approximately 1.5 to 2 cm inferolateral to the lateral canthus. The nasojugal insertion port is horizontally level with the alar crease within the nasojugal groove. The nasolabial insertion port is approximately 1.5 to 2 cm inferolateral to the ipsilateral alar base within the midpoint of the nasolabial fold (Figure 6). Postinjection dissection of the cannula-passage tract revealed penetration of

the SMAS near the insertion site with the dyed hyaluronic acid filler immediately on the undersurface of the SMAS and posterior membranous surface of the orbicularis oculi muscle (Figures 1, 4, and 7). For all injections, a 23-gauge needle was utilized to penetrate the subcutaneous tissue and a 25-gauge blunt cannula was inserted for passage through the remaining tissues. In all port sites, a local anesthetic injection of epinephrine (1:200,000) could be applied to reduce pain and minimize embolism risk secondary to vasoconstriction.

## Medial Midface Viaduct (Beut Technique, Type 1)

### Aesthetic Goal

Restoration of anterior cheek projection and softening of the tear trough will yield a more youthful midface. The



**Figure 3.** This elderly male fresh cadaver underwent a layered dissection of the midface following percutaneous injection of red-dyed hyaluronic acid with blunt cannula. The arcus marginalis was released, revealing the red-stained material within the PZC. The preperiosteal (PP) fat is labeled. The PZC, RS fat, and MS cheek fat are labeled.

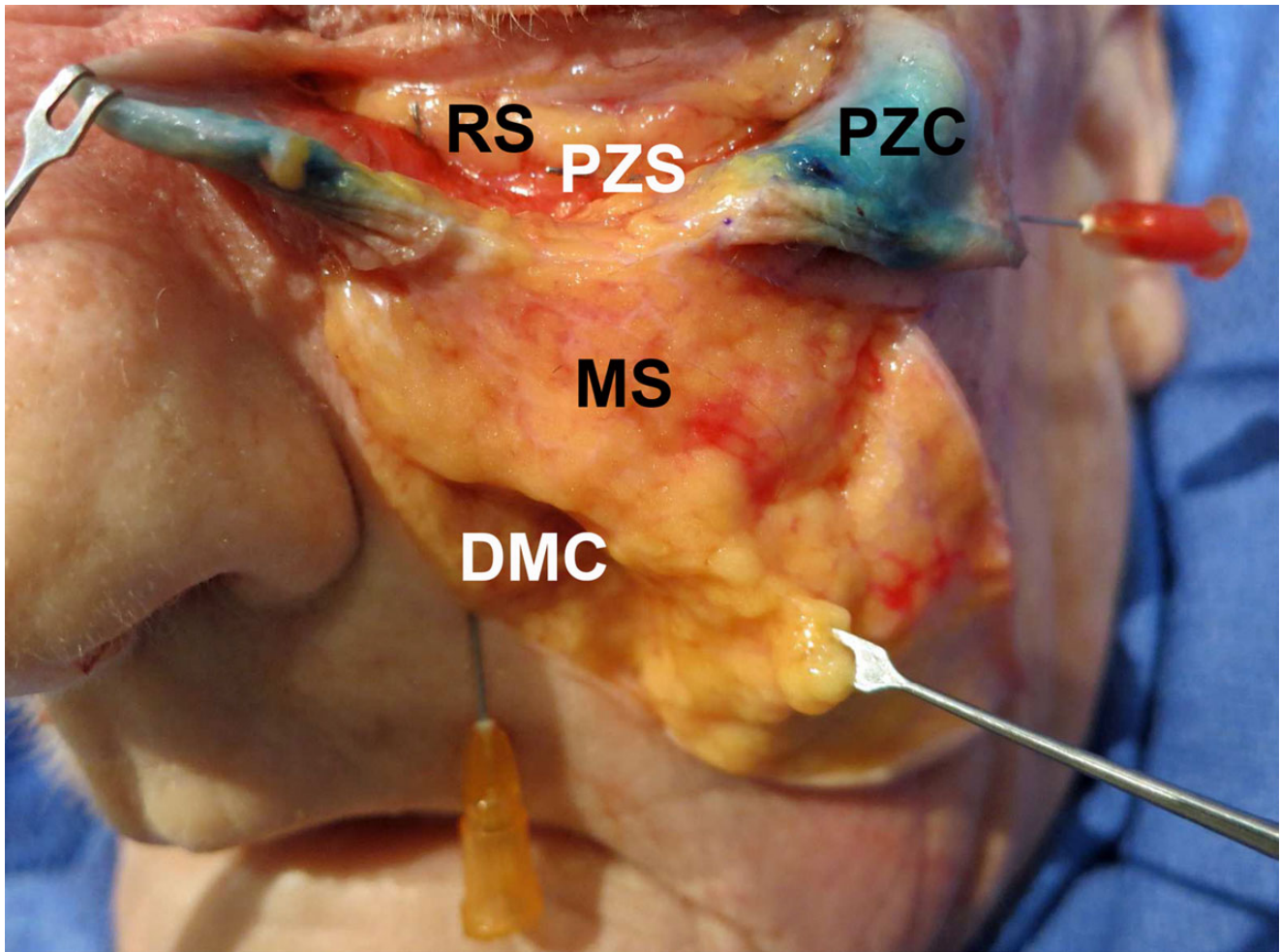
medial midface viaduct has a superior and inferior quadrant. The inferior quadrant contains the DMCF and the premaxillary space.<sup>4,22</sup> The aesthetic goal in the inferior region is restoration of anterior cheek projection, ie, the point of maximum support in the medial midface. The superior quadrant contains the superior portion of the nasolabial fat and the medial aspect of the prezygomatic space. Volumization in this region effaces the tear trough. The objective is not to fill the tear trough but rather to create a single unit between the tear trough and

the superior quadrant of the nasolabial compartment (Supplementary Video, *Beut Type 1*).

### Inferior Quadrant

#### Relevant Anatomy

With aging, the deepened nasolabial fold is multifactorial, but the bony retrusion of the pyriform aperture and the DMCF compartment's volumetric fill are known to be contributory. The DMCF fills a skeletal concavity within the



**Figure 4.** This elderly male fresh cadaver underwent a layered dissection of the midface following percutaneous injection of red-dyed hyaluronic acid with blunt cannula. The arcus marginalis was released to unveil the PZS. Retroseptal fat and MS cheek fat are labeled for orientation. The PZC is dyed with methylene blue. The DMCF compartment is noted in the deeper compartment layer.

maxillary recess and gives support to the nasolabial fat pad. The DMCF is more robust medial to the levator anguli oris (LAO). Lateral to the DMCF, at the level of the alar crease and below, the authors and others have noted inadvertent jowling from injections that intended to volumize the DMCF (Figure 4). These injections have likely missed laterally where the quality of the DMCF becomes more areolar (Figure 5). Location of the LAO by intraoral palpation, noting its intersection with the nasolabial crease, marks the optimal port for cannula volumization of the medial midface. The SMAS of the upper lip is relatively shallow; lateral to the nasolabial crease, the SMAS is attenuated and easily penetrated by a blunt-tipped cannula.

#### **Filler Options**

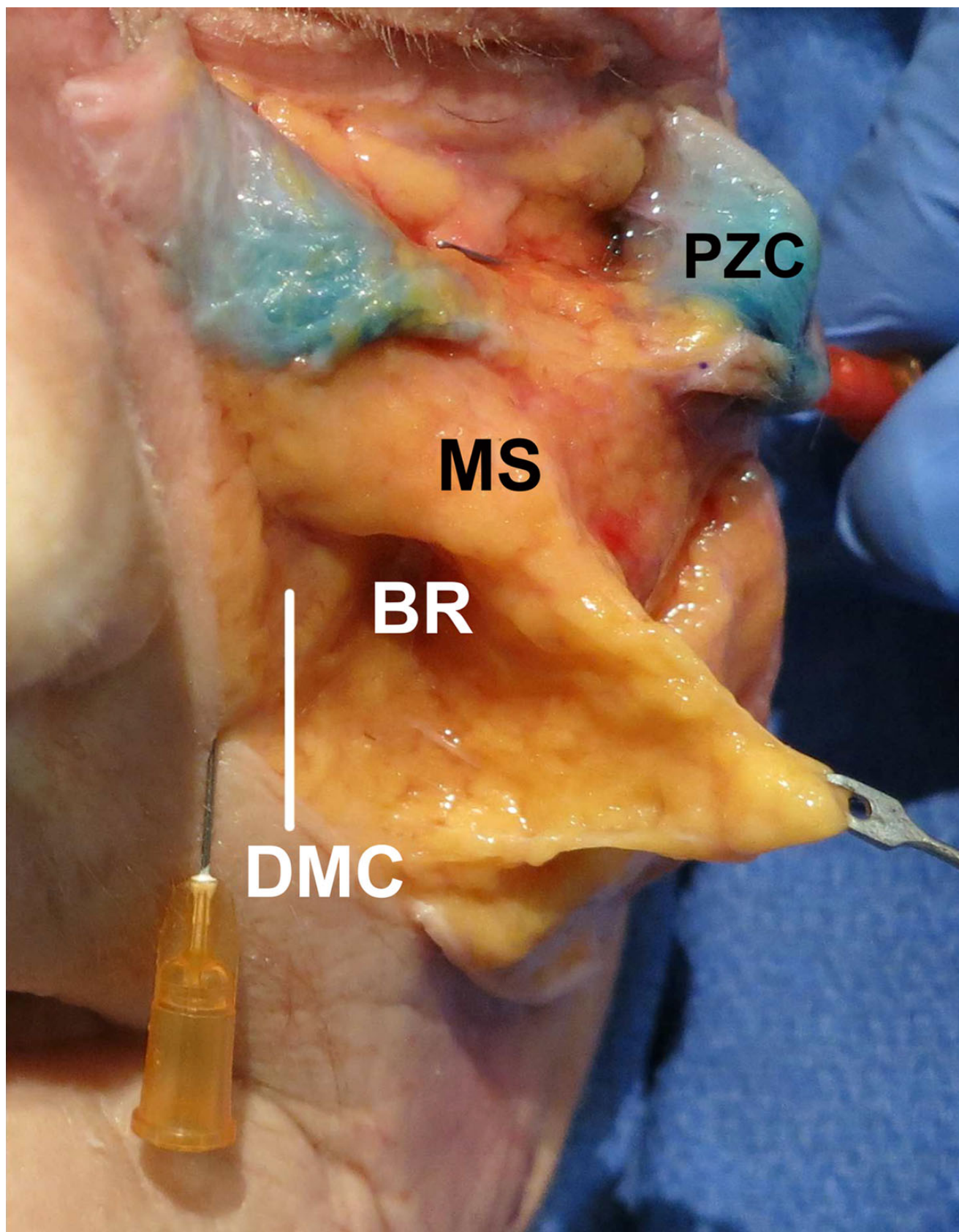
The augmentation objective of the inferior quadrant is to effect projection. Autologous fat or commercial dermal fillers

with large particle size, increased cohesivity, and higher G prime values are recommended. Coleman and others have advanced the preparation and technique for autologous fat grafting. It is not our recommendation that this approach be used for multilevel lipostructure procedures (Figures 1-4).

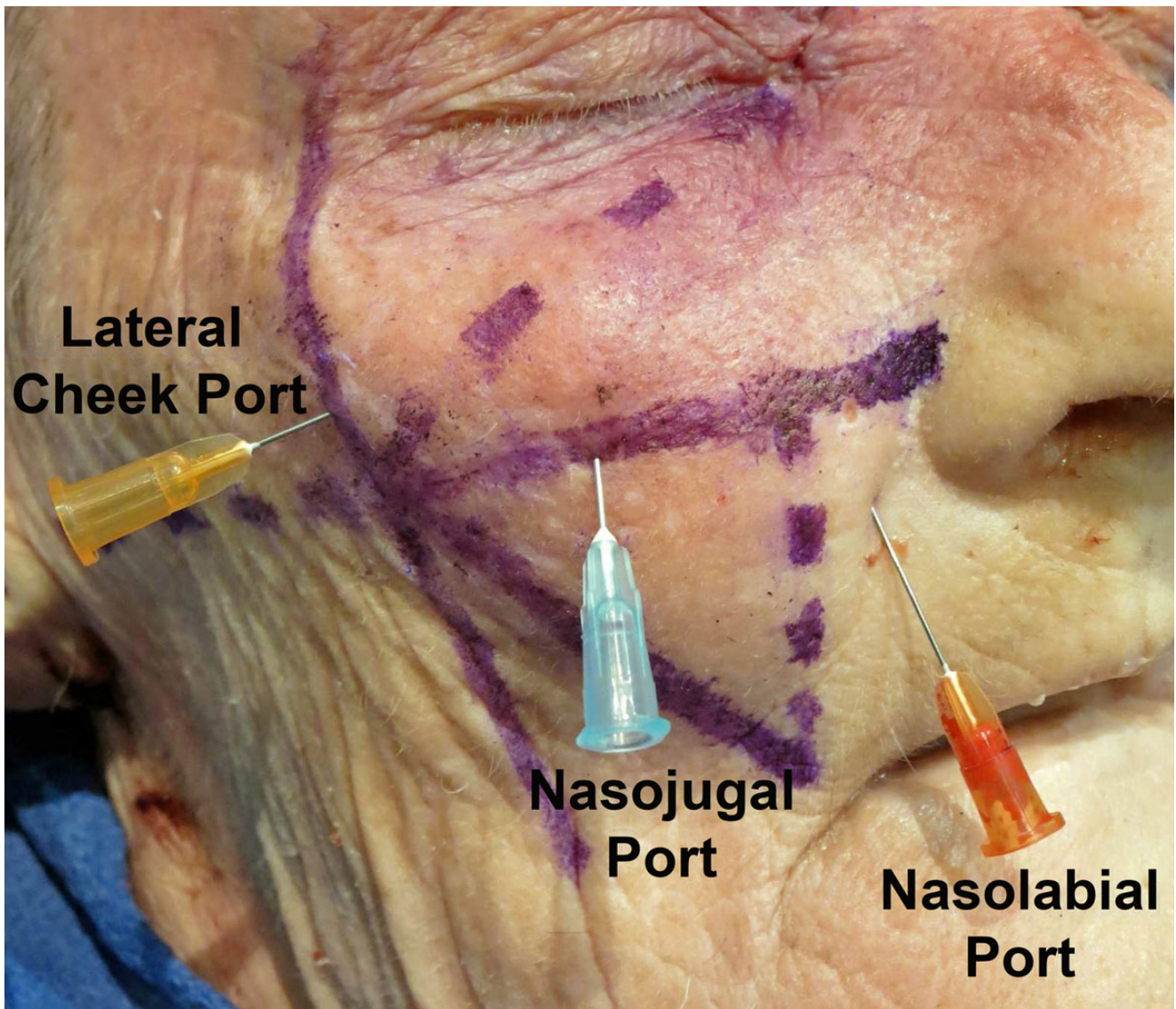
## **Superior Quadrant**

### **Relevant Anatomy**

The orbicularis oculi muscle is continuous with the SMAS below and is invested with a membrane on both its surfaces.<sup>25</sup> The membrane on the undersurface of the orbicularis readily resists penetration by reasonable tangential forces of a blunt cannula. The increased appearance of the tear trough results from the action of the levator labii superioris (LLS), levator labii superioris alaeque nasalis (LLSAN), and the orbicularis oculi, along with the diminished volume of the



**Figure 5.** This elderly male fresh cadaver underwent a layered dissection of the midface following percutaneous injection of red-dyed hyaluronic acid with blunt cannula. The MS cheek fat and the DMCF are labeled for orientation. The PZC is dyed with methylene blue. A cavernous connection in the buccal recess (BR) is noted.



**Figure 6.** This describes the insertion of the medial and lateral midface viaducts on this elderly male fresh cadaver. The nasolabial port is 1.0 cm inferolateral to alar base within the nasolabial fold. The nasojugal port is horizontally level with the alar crease within the nasojugal groove. The lateral cheek port is 1.5 cm inferior-lateral to the lateral canthus.

DMCF and atrophic changes superficial to the orbicularis oculi muscle.

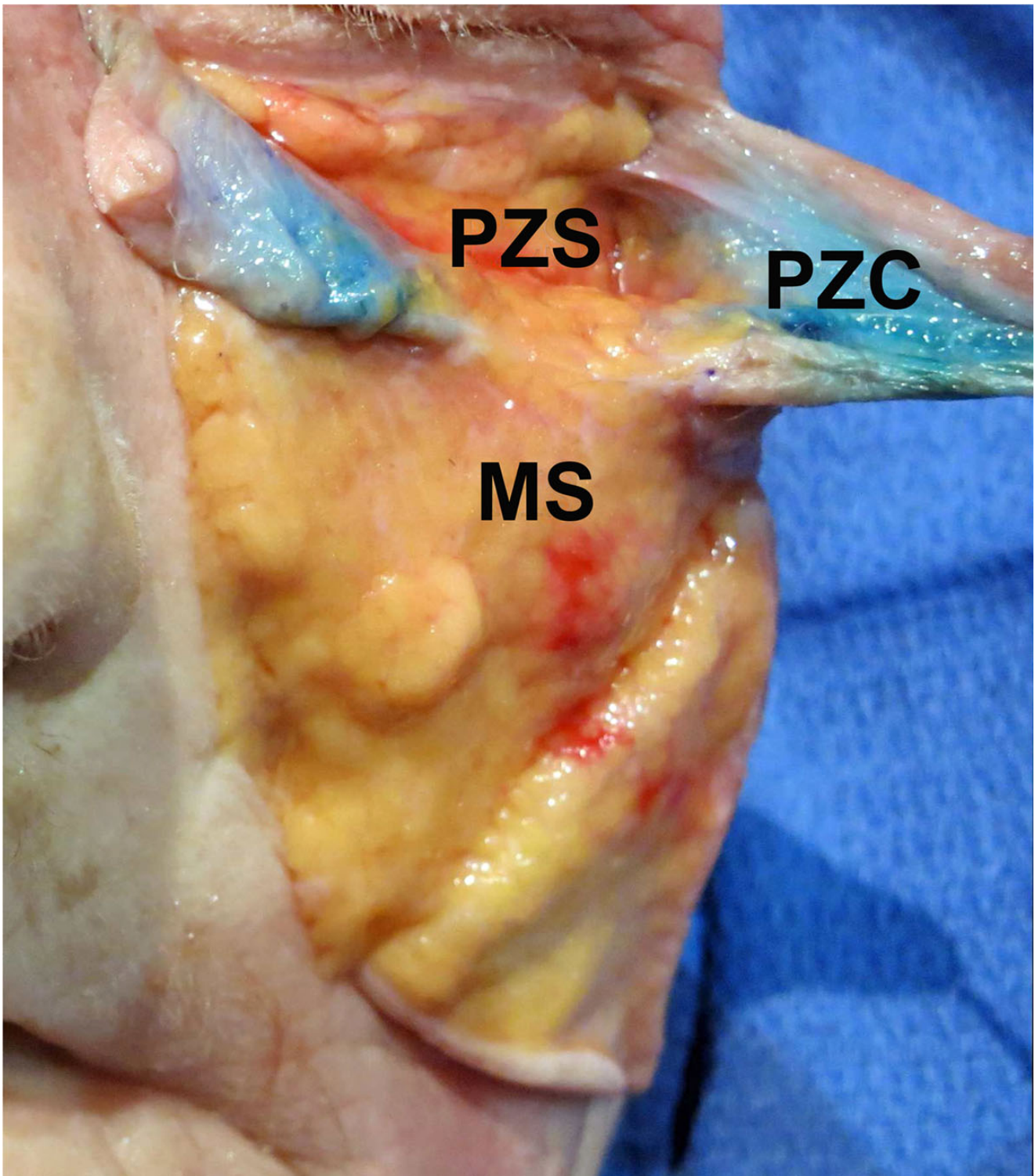
The angular vein courses transversely with intimate relations to the undersurface of the orbital orbicularis and is protected by the orbital retaining ligament (ORL) and inferomedial orbit. The injector must be cognizant of the presence of the angular vein as it courses Cephalic, medially and anterior to the medial canthal structures. Injections extending too medially can create a prominence of the vein along the lateral nasal wall.

The ascending branch of the infraorbital artery courses vertically on the undersurface of the SMAS and the palpebral portion of the orbicularis. The course of the ascending branch is vertical and falls in a vertical line at the medial

pupil line. Diagonal communicating branches between the angular artery and the ascending branch fall in an areolar plane on the undersurface of the SMAS, and blunt cannulas should move past them freely. The confluence of the tear trough ligament, the arcus marginalis, and the orbitomalar ligament's osseous insertion into the malar bone form a stout barrier to cannula penetration into the retroseptal space superiorly. This safety infraorbital rim margin (SIRM) should be palpated and identified prior to injection<sup>27</sup> (Supplementary Video, *Beut Type 1*).

#### **Description of the Beut Technique, Type I**

The superior and inferior quadrants can be accessed through a single port. The nasolabial insertion port consists



**Figure 7.** This elderly male fresh cadaver underwent a layered dissection of the midface following percutaneous injection of red-dyed hyaluronic acid with blunt cannula in the left hemiface. The arcus marginalis was released to unveil the PZS. The MS cheek fat is labeled for orientation. The PZC is dyed with methylene blue.

of an entry point within 1.5 to 2 cm of the alar crease over the nasolabial crease (Figure 6). The location is selected to avoid the areolar superficial buccal branch communicating

with the buccal fat along the lateral side of the approach (Figure 5). Maintain a vertical and deep course to avoid the descending infraorbital artery that runs along the



undersurface of the SMAS, 2 to 4 mm medial to the mid-pupillary line. At this inferior level, the DMCF can be injected. Monitor the topographic change in the nasolabial fold and pyriform aperture for desired results. To approach the superior quadrant, a rotating or screw motion best accomplishes cephalic passage of the cannula. Any attempt at pushing the cannula is not recommended. When easy cephalic passage is gained, the cannula likely is traveling in the premaxillary space, deep to the nasolabial fat compartment and anterior to the LLS (Figures 1 and 4). Resistance will be met at the tear trough-ORL convergence. Injectors should place a finger on the orbital rim for careful monitoring as they pass through the ORL. Caution must be exercised not to inject into the retroseptal fat pad (Figures 2-4).

Injections should be deposited as parallel vertical passes. The material is placed in a triangular stalagmite-type fashion, tapering from larger to smaller aliquots as the cannula is retracted inferiorly (Figure 8). The medial injection should extend 5 mm lateral to the medial canthus (Figure 2). This will avoid creating a venous restriction of the angular vein, which may result in venous prominence just medial to the medial canthus on the lateral nasal wall. This additionally can prevent the sausage-type effect of medial clumping. These parallel stalagmite-type injections should be made medially to laterally, effacing the tear trough. Then, with lateral advancement, the cannula should become slightly oblique in orientation, facilitating continued effacement of the malar groove.

#### **Filler Options**

Filler can be placed in a stalagmite-type fashion (Supplementary Video, *Beut Type 1*). Applying a higher G prime, small-particle hyaluronic acid filler would be effective in this region. Syringe-aspirated autologous fat that is harvested with a small “cheese-grater” cannula, under small syringe negative pressure, could be ideal for this region. Be cautious with large particles in the superior quadrant because we believe that larger particles can block the lymphatics. We recommend a 25-gauge cannula with a small to medium particle size and cohesivity. Small linear threading liposuction technique of autologous fat can be considered if properly placed within the nasolabial compartment.

### **Middle Midfacial Viaduct (Beut Technique, Type 2)**

#### **Aesthetic Goal**

The goal of this technique is to blend the lateral lid-cheek junction. The reduction of the increased vertical height of the lower lid softens the lid-cheek junction. The elongation and vertical reorientation of the orbitomalar ligament is

contributory to the malar groove associated with an aged periorbital.

#### **Description of the Beut Technique, Type 2**

Either the lateral cheek or nasojugal insertion ports should facilitate a cannula insertion that is deep to the inferior orbital rim. Small oblique lines of filler should be placed along the orbital rim, beginning within the space between the orbital septum and orbitomalar ligament and passing inferiorly into the upper limits of the prezygomatic space (Figure 9). Filler should be placed in a parallel stalagmite-type fashion over the concave curvature of the inferomedial orbital rim. The objective is not to “fill the gap” but to fuse and blend the lower lid and cheek in a dynamic fashion. Single injections (ie, filling gaps) can create a double fold when the patient smiles, facilitating a less natural look with movement and heaviness to the face.

#### **Filler Options**

For lid-cheek blending, we suggest utilizing a small to medium particle-sized filler with a higher G prime value (Supplementary Video, *Beut Type 2*).

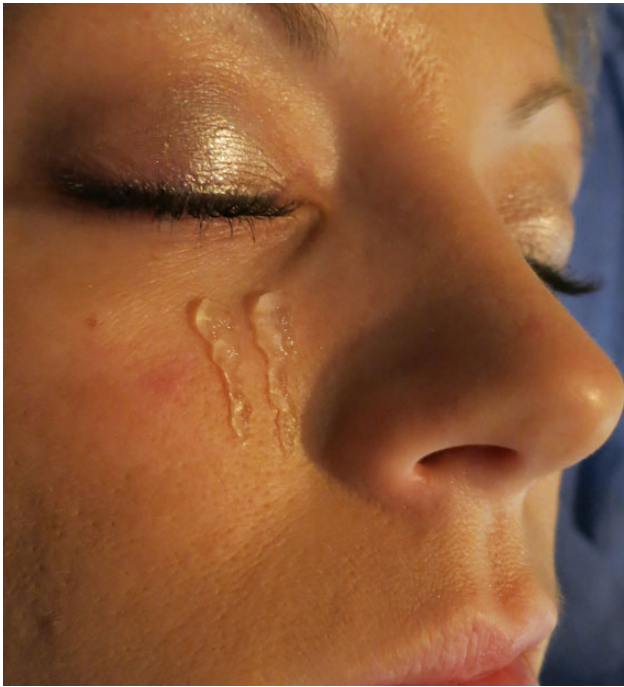### **LATERAL MIDFACE VIADUCT (Beut Technique, Type 3)**

#### **Aesthetic Goal**

A continuous harmonious ogee curve to the cheek connotes youth and beauty. Restoration of an oval-shaped orbit restores this youthful appearance. Creating an anterolateral projection and will provide support for blending the targets of the midface. Depending on the need for volumization and shape or projection and support in select patients, augmentation of the prezygomatic space or deep on the lateral zygoma can be performed (Figures 2, 3, and 7).

#### **Relevant Anatomy**

With aging, the orbitomalar and palpebral ligaments become elongated and vertically oriented between their malar origins and the point where they pierce the orbicularis oculi. The arcus marginalis and the orbitomalar ligament, an elastin-containing sheet-like structure, form the roof of the prezygomatic space.<sup>25</sup> Our anatomic dissections, exploring the relations of the V-groove deformity of aging, show a close correlation between the lateral limb of the groove and the caudal edge of the inferocentral and inferolateral orbicularis oculi muscle. Based upon this relationship, we postulate a bucket-handle effect is caused by the loss of volume within the components of the suborbicularis fat cephalic to the zygomatic retaining ligaments. This leads to inherent loss of support. Recent research has delineated the difference

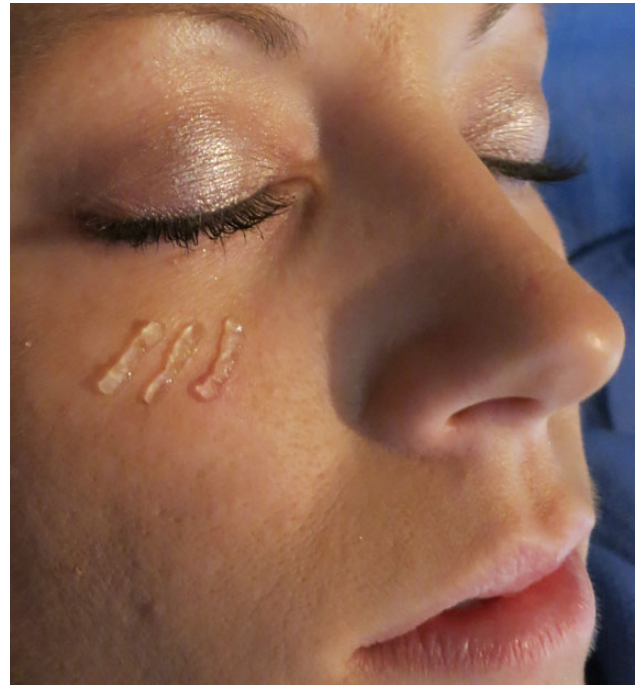

**Figure 8.** This 29-year-old female patient model underwent a demonstration of filler location, in *Beut Type 1*, for tear trough effacement and volumization of the superior nasolabial fat pad. Note the stalagmite-type deposition of the filler, with large amounts placed superiorly and the tapering of filler inferiorly.

between the PP fat and the SOOF (Bryan Mendelson, verbal & written communication, January 2014). The PP fat is deep to the pre-zygomatic space (Figure 3). The SOOF lies superficial to the PP fat, deep to the orbicularis oculi muscle, and maintains a loose areolar consistency. Encapsulating the pre-zygomatic space is a uniform fibrous lining that, begins superficially at the posterior capsule of the orbicularis oculi muscle, traverses inferiorly within the zygomatico-cutaneous ligaments, and ascends over the PP fat to coalesce with the arcus marginalis-orbitomalar ligament junction (Figures 1-5 and 7).

### **Description of the Beut Technique, Type 3**

The injector must first determine whether lateral cheek projection or a V-groove effacement with volumization is needed for the patient. An accurate analysis is mandatory to achieve optimal results with this technique.<sup>24,26-33</sup> Analysis should be performed by standing behind the patient, obtaining a bird's-eye view to assess dimensions in the area of maximum cheek projection. Projection (3a) and volume (3b) should be performed in the same midface region but at distinctly different anatomical layers (Supplementary Video, *Beut Type 3*).



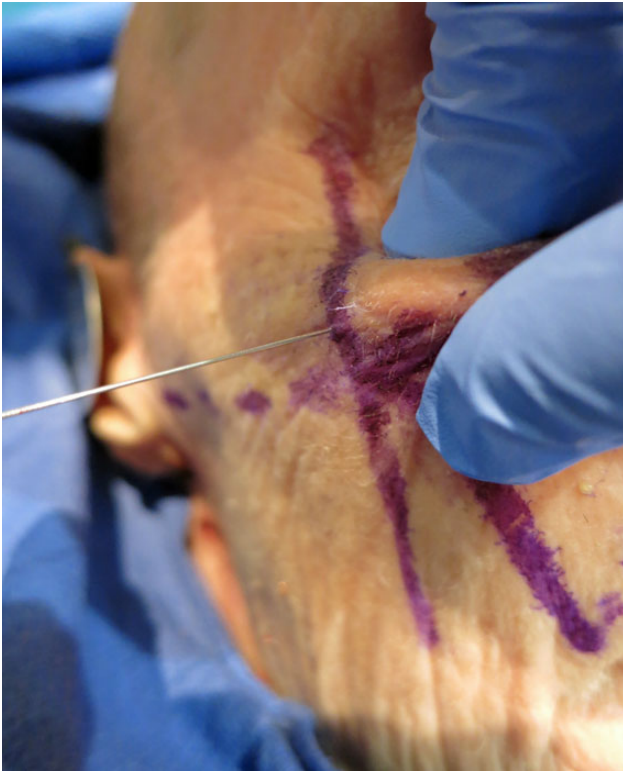**Figure 9.** This 29-year-old female patient model underwent a demonstration of filler location, in *Beut Type 2*, for lid-cheek blending. Note the oblique vector of filler deposition.

### **Description of the Beut Technique, Type 3a: Projection**

Following needle puncture, a 21-gauge cannula should be inserted through the lateral cheek insertion port in line with the supratarsal fold, 2 cm from the lateral canthus (Figure 6). Insert the cannula in a steep downward motion while performing a “pinch and pull” technique upward of the palpebral orbicularis oculi muscle. The cannula should be advanced caudally and deeply until the injector meets resistance at the posterior membranous fascia of the orbicularis oculi forming the lateral component of the prezygomatic space capsule (Figures 1, 4, 5, 7, and 10). Proceed past the “pop” and orient the cannula transversely and glide over the zygoma. Passage into the prezygomatic space (Supplementary Video, *Beut Type 3*) can be confirmed through a “cannula test”—when the cannula passes over thin granular periosteum and the injector can feel the texture of the bone (Figure 11).

The injector should obtain a bird's-eye view from behind the patient and identify the location of maximum cheek projection for the patient. A bolus injection can be inserted, watching for “tenting” of the skin and topographical anterior excursion of malar tissue, until desired cheek projection has been achieved.

This injection consists of a bolus on the bone with minimal tunneling (Supplementary Video, *Beut Type 3*). Before extracting the cannula, remove the syringe and inject normal saline to flush the remaining product into the



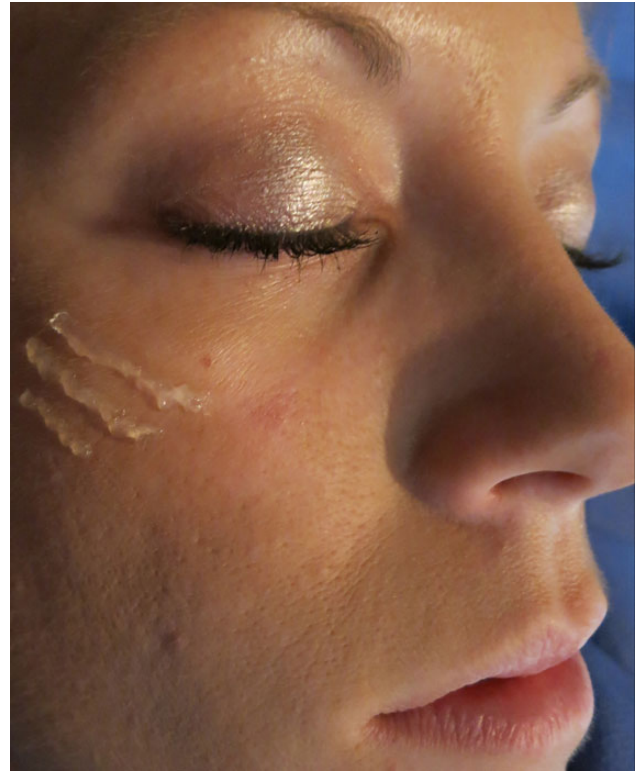**Figure 10.** This elderly male fresh cadaver underwent a demonstration of the pinch and pull technique for penetration of a blunt cannula into the suborbicularis plane into the PZS.

space. The placement of large particles is safe in this technique, secondary to appropriate depth. This injection is deep within the prezygomatic space and the topographical change is likened to the effect of a silicone cheek implant. However, if the cannula is misplaced superficially, the large particle-sized filler will be visible underneath the skin. As a result, unwanted skin irregularities can occur along with an unnatural movement of the face.

#### **Description of the Beut Technique, Type 3b: Volume**

Effective effacement of the lateral V-groove deformity requires volumetric replacement and harmonization of the face, targeting between the midpupillary line and lateral orbital rim. In thin patients, the cannula should be maintained deep to the orbicularis oculi muscle. This should be performed through the nasolabial insertion port. Cannula passage into the suborbicularis plane and within the prezygomatic space can be ensured through a pinch and pull of the cheek just below the lower eyelid and in line with the lateral canthus.

In our anatomic dissections, we noted ethnic variations in the posterior membranous capsule of the orbicularis where some were exceedingly difficult to pierce with a blunt cannula. The encapsulation of the prezygomatic space resists



**Figure 11.** This 29-year-old female patient model underwent a demonstration of filler location, in *Beut Type 3a*, for maximum cheek projection.

filler material migrating caudally to the inferior border of this space that comprises the zygomatico-cutaneous ligaments (Figure 1). Pass medially to a point just lateral to the placement of volumetric filler through the medial access viaduct (Figures 1-4). Once the desired volumization has been placed in the inferocentral prezygomatic space, inferolateral volumization as well as pure lateral volumization can be achieved without removal of the cannula. This can be accomplished by changing the angulation and directing the cannula over the anterolateral zygoma, staying caudally to the lateral canthal mechanism.

A lateral vector in a superficial plane can be taken with a blunt cannula to perform a carefully calculated fill that is cephalic and lateral to the zygomatico-cutaneous ligaments. This can be determined during the injector's preprocedure facial analysis. In patients who are not excessively thin, the end result should be a greater radius of the cheek. We propose occluding the area with an occlusive dressing (ie, 3M Tegaderm, St. Paul, MN) for 24 hours to reduce edema.

#### **Filler Options**

Autologous fat can be utilized in both volumization and projection techniques. Small aliquots with gentle massage should be performed to desired effect. Placement of

autologous fat in the prezygomatic space has been presented by Marten, who has reported high graft survival rates (Tim Marten, verbal communication, October 2013 & January 2014). Depending on cannula depth, volumization can be achieved with small to medium particle-sized fillers. Projection in the suborbicularis plane should use large particle-sized fillers with high cohesivity and G prime values (Supplementary Video, *Beut Type 3*).

## Superficial Volumization (Beut Technique, Type 4)

### Aesthetic Goal

Following replenishment of the midfacial viaducts, this technique facilitates augmentation and blending of the superficial cheek fat concavities. The concavities form clefts such as the nasojugal fold that are responsible for malar folds and rhytids. The goal is to avoid the heaviness seen in patients who have received single injections to fill a cleft or rhytid. This “hole” filling increases the vectors of Langer’s lines. In technique 4, however, filler placement creates a scaffolding support of Langer’s lines, ultimately obtaining a smooth transition with dynamic action and movement (Supplementary Video, *Beut Type 4*).

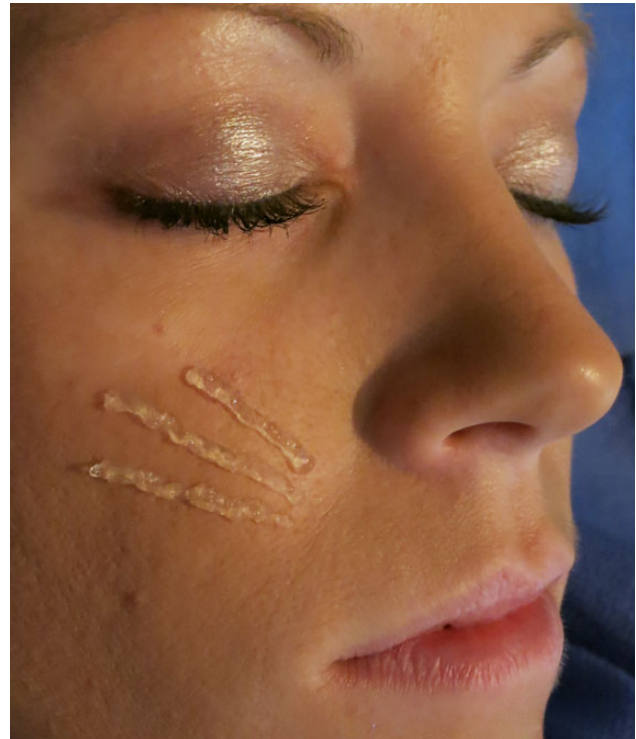### Anatomy

The superficial midface cheek fat consists of the nasolabial, infraorbital, medial superficial, middle superficial, and lateral superficial cheek fat (Figure 1). Limited compartment overlap has been noted in the transition zones. The medial superficial (MS) compartment is thinner medially and thicker laterally (Figure 4). The compartment is fibrofatty in nature and more dense laterally to the maxillary projection and zygomaticus major muscle.

### Description of the Beut Technique, Type 4

A blunt cannula should be inserted through the nasolabial insertion port and maintained at a superficial depth of < .75 cm (Figure 6). If the cannula travels too deep, the filler may fall into the buccal recess. In addition, the injector must maintain the appropriate vector to prevent malposition of material (Figure 5). The vector should be situated in a superficial plane at the junction of the medial and middle superficial cheek compartments, appropriately fanning medially and laterally to blend adjacent compartments (Figure 12). The injector must take care to avoid excessive manipulation of the malar infraorbital fat pad (Figure 2). To avoid lymphatic dysregulation within the thin lower eyelid skin, needle injections should not go cephalad to the orbitomalar ligament.

Langer’s lines are collagen and elastin bundles that expand perpendicular to their direction of travel. Injections should be performed in a path perpendicular to the cheek sulcus and perpendicular to Langer’s lines. Correction of



**Figure 12.** This 29-year-old female patient model underwent a demonstration of filler location, in *Beut Type 4*, for superficial volumization and compartment blending. Note the deposition of filler is perpendicular to Langer’s lines.

prominent clefts can be effected by volumization in an “opposite-vector” fashion; dotted lines can be drawn on the face to assist if needed (Supplementary Video, *Beut Type 4*). The authors refer to this technique as the “brick effect.”

### Filler Options

Autologous fat, less-stiff hyaluronic acid, or a reactive filler such as poly-L-lactic acid (PLLA) can be utilized for this technique. Heavy particle material is not recommended because it can result in a less natural movement during dynamic phases of animation (Supplementary Video, *Beut Type 4*).

## DISCUSSION

Several different techniques regarding nonsurgical rejuvenation of the midface have been published.<sup>24,28,33-40</sup> Challenges in preserving enhancement during dynamic facial movement renders the midface a complex treatment area. While some authors target facial grooves for filler deposition, others have injected combinations of deep boluses and/or microdroplets.<sup>34-40</sup> In one case series, to accentuate dynamic malar shape, PLLA was injected into HIV lipotrophic patients while they were smiling.<sup>35</sup> We aim to provide shape and support by volumizing the compartments and

spaces where volume loss and descent has occurred with the aging process. This is performed while the patient is reposed and after the patient has been analyzed in both static and dynamic animation. The intent is to provide a scaffolding effect through augmenting deeper structures and progressing superficially until the desired midfacial contour is achieved. Blunt cannula infiltration provides a level of protection from inadvertently traversing multiple tissue planes or entering vessels.

Beut techniques 1 through 4 can be utilized for both autologous fat and commercial dermal filler injections. Fat has a uniform density, whereas fillers possess different densities, particle size, and deformation coefficients.<sup>24,26,31-39</sup> Because of the variety in composition and longevity of fillers, the ability to tailor the injectable to specific aesthetic goals is a proposed advantage in the midface. Each technique targets a group of anatomical structures, rendering certain filler characteristics (G prime, cohesivity, permanence) to be desirable in that region.

Methods for fat harvesting and graft deposition continue to evolve. Attention is currently centered on the regenerative properties of autologous fat, posing an advantage for facial fat grafting in select patients.<sup>40-43</sup> One concern is the ability of the fat to obtain vascularity in potential spaces such as the prezygomatic space. Clinically, we and others have seen satisfactory results in fat retainment following percutaneous blunt cannula injection into the prezygomatic space and facial fat compartments. Further research will need to be performed to quantify the regenerative and surviving capabilities of autologous fat in facial rejuvenation.

The main limitation of this study is that it is a cadaveric study. The techniques described are the summation of 3 practitioners' collective experience over several years of performing midfacial injections. The primary goal of this study was to associate aesthetically significant anatomy with these techniques in order to improve safety, accuracy, and rejuvenation outcomes in midface volumization. An additional limitation in this study is the absence of all demographic (age and gender) information on the 5 hemifacial dissections that were performed during national meeting cadaver courses as well as gender information about the dissections performed at KCUMB.

## CONCLUSIONS

We propose treating the midface through defined viaducts with specific aesthetic goals while maintaining a rejuvenated global expression. The techniques described in this study are derived from demonstrated relationships between midfacial anatomy and injected materials, with appropriate consideration of aesthetic principles. We have defined vectors and depths for procedural ease and accuracy. Anterior and lateral cheek projection, V-deformity correction, rhytid softening, and tear trough effacement can be achieved through the midfacial viaducts. Systematic assessment and site-specific

nonsurgical rejuvenation of the midface may lead to increased safety, accuracy, and technique reproducibility in this commonly injected region.

## Supplementary Material

A set of videos demonstrating each technique may be viewed at [www.aestheticsurgeryjournal.com](http://www.aestheticsurgeryjournal.com) or [www.surgery.org/videos](http://www.surgery.org/videos).

## Disclosures

Javier Beut has been a consultant for Q-Med. The remaining authors do not declare potential conflicts of interest with respect to the research, authorship and publication of this article.

## Funding

The supplemental digital content videos were funded by the Department of Plastic Surgery at the University of Kansas Medical Center. The authors received no other financial support for the research, authorship, and publication of this article.

## REFERENCES

1. Rohrich R, Pessa J. The fat compartments of the face: anatomy and clinical implications for cosmetic surgery. *Plast Reconstr Surg*. 2007;119(7):2219-2227.
2. Stuzin J, Baker T, Gordon H. The relationship of the superficial and deep facial fascias: Relevance to Rhytidectomy and Aging. *Plast Reconstr Surg*. 1992;89:441.
3. Furnas D. Festoons, mounds and bags of the eyelids and cheek. *Clin Plast Surg*. 1993;20:367.
4. Rohrich R, Pessa J, Rustow B. The youthful cheek and the deep medial fat compartment. *Plast Reconstr Surg*. 2008;121(6):2107-2112.
5. Rohrich R, Pessa J. The retaining system of the face: histologic evidence of septal boundaries of the subcutaneous fat compartments. *Plast Reconstr Surg*. 2008;121(5):1804-1809.
6. Aiache A, Ramirez O. The suborbicularis oculi fat pads: An anatomic and clinical study. *Plast Reconstr Surg*. 1995;95:37.
7. Rohrich R, Arbique G, Wong C, Brown S, Pessa J. The Anatomy of Suborbicularis Fat: Implications for Periorbital Rejuvenation. *Plast Reconstr Surg*. 2009;124(3):946-951.
8. Stuzin J, Wagstrom L, Kawamoto H. The anatomy and clinical applications of the buccal fat pad. *Plast Reconstr Surg*. 1990;85:29.
9. Jackson I. Anatomy of the buccal fat pad and its clinical significance. *Plast Reconstr Surg*. 1999;103:2059.
10. Zhang H, Yan Y, Qi K, Wang J, Liu Z. Anatomical Structure of the Buccal Fat Pad and Its Clinical Application. *Plast Reconstr Surg*. 2002;109:7.
11. Little J. Volumetric perceptions in midfacial aging with altered priorities for rejuvenation. *Plast Reconstr Surg*. 2000;105:252.
12. Mendleson B, Muzaffar A, Adams W. Surgical anatomy of the midcheek and malar mounds. *Plast Reconstr Surg*. 2002;110:885-896; discussion 897-911.
13. Mendleson B, Jacobson S. Surgical anatomy of the midcheek: Facial layers, spaces and the midcheek segments. *Clin Plast Surg*. 2008;35:395-404; discussion 393.

14. Mendelson B, Wong C. *Anatomy of the aging face*. Volume 2, Chapter 6. Plastic Surgery, 3rd Edition. New York: Elsevier, Pp. 78-92.
15. Owsley J. Lifting the malar fat pad for correction of prominent nasolabial folds. *Plast Reconstr Surg*. 1993;91:463-474; discussion 475-76.
16. Ghavami A, Pessa J, Janis J, Khosla R, Reece E, Rohrich R. The orbicularis retaining ligament of the medial orbit: closing the circle. *Plast Reconstr Surg*. 2008;121(3):994-1001.
17. Sandoval S, Cox J, Koshy J, Hatef D, Hollier L. Facial fat compartments: a guide to filler placement. *Semin Plast Surg*. 2009;23(4):283-286.
18. Hirmand H. Anatomy and nonsurgical correction of tear trough deformity. *Plast Reconstr Surg*. 2010;125(2):699-708.
19. Gierloff M, Stohring C, Buder T, Gassling V, Acil Y, Wiltfang J. Aging changes of the midfacial fat compartments: a computed tomographic study. *Plast Reconstr Surg*. 2012;129(1):263-273.
20. Pessa J, Rohrich R. Discussion: aging changes of the midfacial fat compartments: a computed tomography study. *Plast Reconstr Surg*. 2012;129(1):274-275.
21. Pessa J, Rohrich R. *Facial Topography: Clinical Anatomy of the Face*. Quality Medical Publishing. St. Louis, 2012.
22. Wong C, Mendelson B. Facial soft tissue spaces and retaining ligaments of the midcheek: defining the premaxillary space. *Plast Reconstr Surg*. 2013;132(1):49-56.
23. Pessa J, Nguyen H, John G, Scherer P. The anatomical basis of wrinkles. *Aesthet Surg J*. 2014;34(2):227-234.
24. Jelks G, Lamb J, Surek C. 'Anatomy of the Facial Fat Compartments – A New Interpretation' RADAR resource. *American Society of Aesthetic Plastic Surgeons*. Web. 3/4/14.
25. Kikkawa D, Lemke B, Dortzbach R. Relations of the Superficial Musculoaponeurotic System to the Orbit and Characterization of the Orbitomalar Ligament. *Ophthalmic Plast Reconstr Surg*. 1992;12(2):77-88.
26. Beut J. 'Restylane Sub-Q clinical study' XLI Congress of the Spanish Society of Aesthetic. 2006.
27. Beut J. Prospective, longitudinal, controlled evaluation and validation of the clinical accuracy, precision and operating characteristics of non-invasive methods of detection as compared to magnetic resonance imaging in soft tissue volume augmentation of malar eminence provided by cross-linked biosynthesized hyaluronic acid fill (Restylane SubQ). FDA Trial: 2006-2007.
28. Beut J, Jelks G. New Algorithm for Non-Surgical Rejuvenation. Presented at Beut & Jelks Oculoplastic Symposium. Palma De Mallorca, Spain, 2009.
29. Beut J, Guisantes E. An Algorithm for Non-Surgical Rejuvenation. Presented at International Master Course on Aging Skin (IMCAS). Paris, France, 2009.
30. Beut J, Jelks G. Anatomy of the peri-ocular area and treatment: Stalagmite Technique. Presented at Beut & Jelks Oculoplastic Symposium. Palma De Mallorca, Spain, 2010.
31. Beut J. New Trends in Injectables. Presented at International Master Course on Aging Skin (IMCAS). January, 2011; Paris, France.
32. Beut J. Video: 'New Facial Algorithms'. 1st Prize Recipient, 1st Cannes International Aesthetic Film Festival. F.A.C.E. 2 F@ce Congress 2012.
33. Jelks G. Anatomy and Evaluation of Aging Changes in Lower Lid. Presented at ASAPS 2014 Las Vegas Aesthetic Symposium. January 2014.
34. Gilbert E, Calvisi L. Midface and perioral volume restoration: a conversion between the US and Italy. *J Drugs Dermatol*. 2014;13(1):67-74.
35. Wang A, Babalao O, Jagdeo J. The 'smile and fill' injection technique: a dynamic approach to midface volumization. *J Drugs Dermatol*. 2014;13(3):288-290.
36. Hirmand H. Anatomy and non-surgical correction of the tear trough deformity. *Plast Reconstr Surg*. 2010;125(2):688-708.
37. Carruthers J, Rzany B, Sattler G, Carruthers A. Anatomic guidelines for augmentation of the cheek and infraorbital hollow. *Dermatol Surg*. 2012;38(7):1223-1233.
38. Rohrich R, Hanke W, et al. Facial Soft Tissue Fillers Conference: Assessing the State of the Science. *Plast Reconstr Surg*. 2011;127:22S-122e.
39. Lorenc ZP. Techniques for the optimization of facial and nonfacial volumization with injectable poly-L-lactic acid. *Aesthetic Plast Surg*. 2012;36(5):1222-1229.
40. Donofrio L. Techniques in facial fat grafting. *Aesthet Surg J*. 2008;28(6):681-687.
41. Gerth D, King B, Rabach L, et al. Long-term volumetric retention of autologous fat grafting processed with closed-membrane filtration. *Aesthet Surg J*. 2014;34(7):985-994.
42. Hsu V, Stransky C, Bucky L, et al. Fat Grafting's Past, Present and Future: Why Adipose Tissue is Emerging as a Critical Link to the Advancement of Regenerative Medicine. *Aesthet Surg J*. 2012;32(7):892-899.
43. Sajjadain A, Magge K. Treating Facial Soft Tissue Deficiency: Fat Grafting and Adipose-Derived Stem Cell Tissue Engineering. *Aesthet Surg J*. 2007;27(1):100-104.